

Successful Intubation of a Trauma Patient with Cervical Spine Fracture via the King Vision™ Video Laryngoscope (KV)



Bracken D §,* , Samuels JD §

Department of Anesthesiology §, Weill Cornell Medical College, New York, NY

Introduction:

The optimal method by which to secure the airway of a patient with a cervical spine injury remains controversial. In non-emergent situations, it appears that awake intubation over a flexible bronchoscope is preferred as it reduces cervical spine motion in cadavers. In emergencies, however, direct laryngoscopy is quicker and less affected by blood/airway secretions, but causes more cervical spine motion and can potentially result in devastating neurologic injury. Alternative techniques have been examined, including different laryngoscope blades, LMAs, and indirect rigid fiberoptic laryngoscopes. Video laryngoscopy has recently become more developed and more widely available. It combines the advantages of both fiberoptic bronchoscopy and direct laryngoscopy. The following is a case report of a successful intubation of cervical spine injured adult with the King Vision™ video laryngoscope.

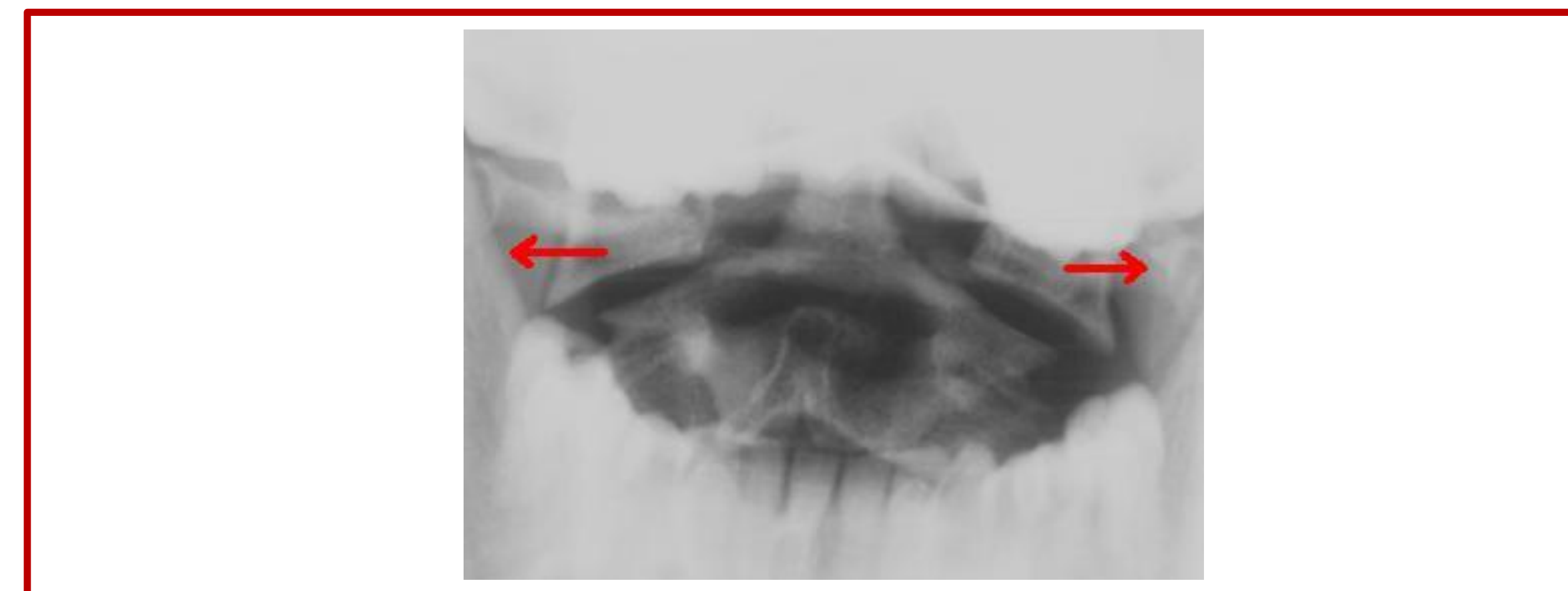
Case Report:

66-year old male patient admitted to the trauma service after pedestrian struck, who incurred multiple injuries including C1 fracture with extension into foramen magnum. He was taken to the operating room for ORIF of his left ankle and right tibia nailing. He arrived wearing a rigid cervical collar, which was removed; he was subsequently orally intubated with the King Vision video laryngoscope utilizing manual in-line stabilization under general anesthesia with rapid sequence induction. The intubation attempt was easy, atraumatic, and was achieved in less than 15 seconds.

Fig. 1. Arrows show lateral offset of C1 on C2. Fig. 2. A) OA Oral axis PA Pharyngeal axis LA Laryngeal axis. Fig. 4. King Vision™ Video Laryngoscope



• **Figure 1. Jefferson fracture**



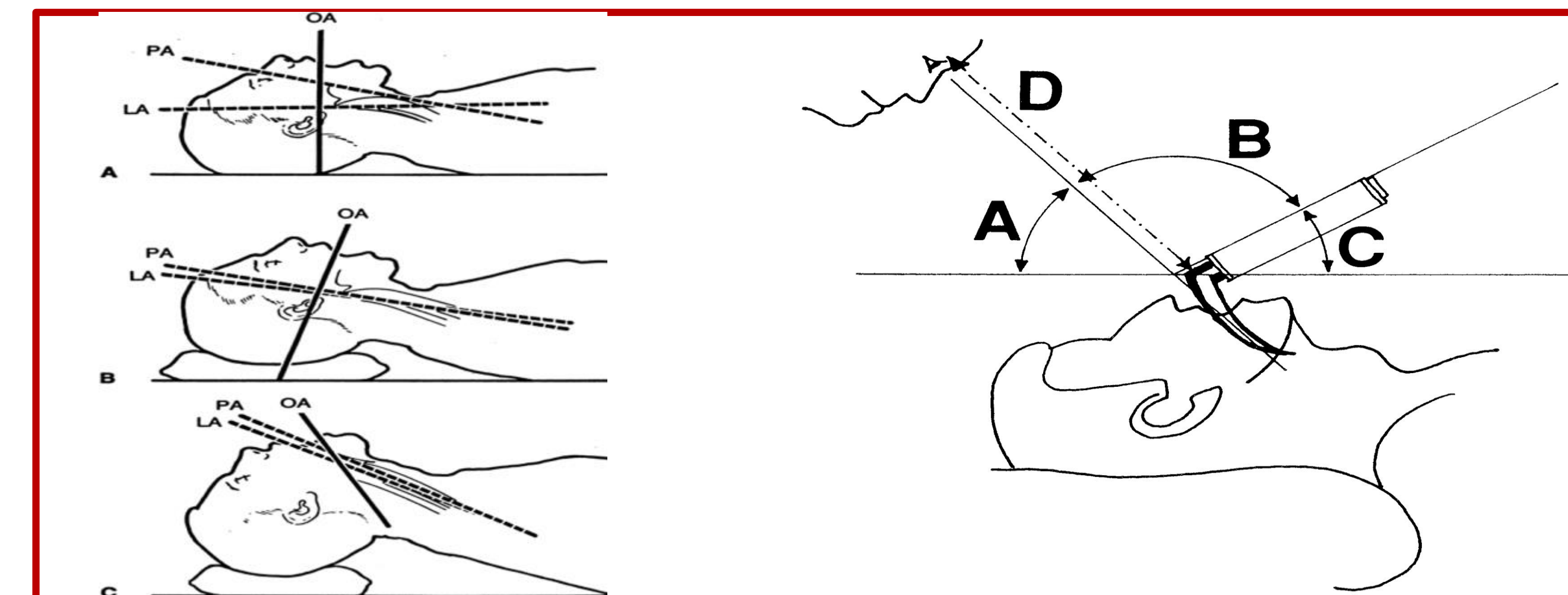
• Figure 1. Open-mouth cervical x-ray showing burst bilateral fractures.

• **Title of Figure Three**



• Figure caption

• **Figure 2. DL. A) Axes B) Line-of-sight**



• Figure caption

• **Fig 4. King Vision™ Video Laryngoscope**

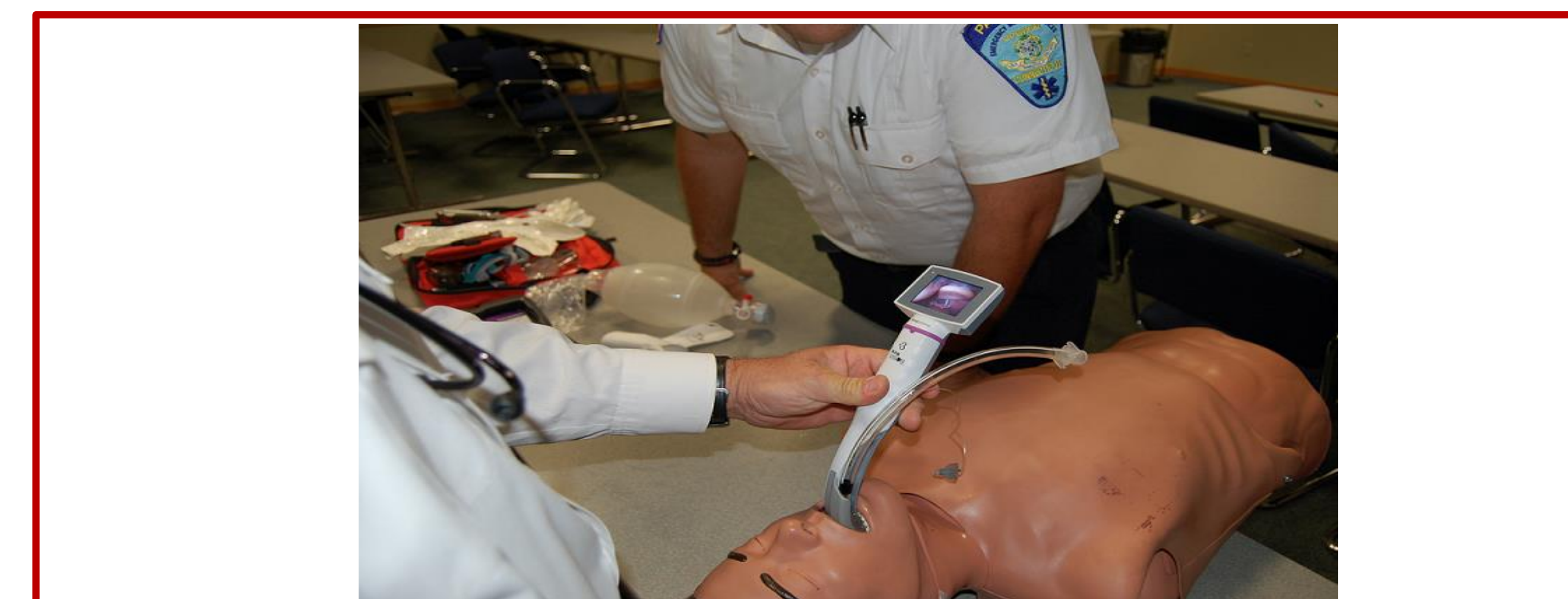

Figure 4. King Vision™ channelled scope inserted in neutral neck position.

Methods:

Remember that a poster is NOT a full manuscript. It should be formatted to make the essence of the work clear to people who are browsing the poster session. Determine the key elements of the work and emphasize them. You will have an opportunity to discuss finer details with people who are interested and talk with you.

Tracheal intubation devices not requiring cervical spine extension:

- Fiberoptic bronchoscopy
- Airtraq™, Airtraq Avant™
- LMA Fastrach™

Requiring reduced cervical spine extension:

- Storz C-MAC™
- McGrath MAC VL™
- GlideScope™
- Bonfils Retromolar Intubation Fiberscope™
- Malleable fiberoptic stylets: Shikani™, Levitan FPS™

Advantages of the KV:

- OLED: superior optics. No need for fiberoptic towers or external light sources.
- Completely portable (ICU, ED, etc)
- Affordable
- No special chargers or batteries
- Excellent ramp for fiberoptics
- May be assembled after placement in patient. Good for short neck, hard collar
- Minimal mouth opening: 18 mm

Conclusions:

- The KV appears to be a safe airway management device for the patient requiring no neck manipulation
- Formal study is required

References

Jefferson G. Fracture of atlas vertebrae: report of four cases and a review of those previously recorded. Br J Surg 1920; 7:407–422.
 Norris AM, Hardman JG, Asai T. A firm foundation for progress in airway management. Br J Anaesth 2011;106(5):613–616.